https://revistas.udelar.edu.uy/OJS/index.php/anfamed/index
ISSN-e: 2301-1254

IMÁGENES BIOMÉDICAS
DOI: 10.25184/anfamed2026v13n2a4
An Facultad Med (Univ Repúb Urug). 2026; 13(2): e701

Pachydermoperiostosis: imaging findings and differential diagnosis

Paquidermoperiostosis: hallazgos por imagen y diagnóstico diferencial

Paquidermoperiostose: achados de imagem e diagnóstico diferencial

VICTOR SUDÁRIO TAKAHASHI[1], LAURA GABRIELA SILVA[2], JOSÉ LUIZ MASSON DE ALMEIDA PRADO[3], MÁRCIO LUÍS DUARTE[4]

(1) Universidade de Ribeirão Preto - Campus Guarujá, Guarujá (SP), Brazil.

Correo eletrónico:
sudario.takahashi@gmail.com
ORCID: 0000-0003-0330-6681

(2) Faculdade de Medicina, Centro Universitário Atenas. Paracatu (MG), Brazil.

Correo eletrónico:
lauragaby01@gmail.com

ORCID: 0000-0002-8292-4295

(3) Fleury Medicina e Saúde. São Paulo (SP), Brazil.

Correo eletrônico:
jlmap1976@gmail.com

ORCID: 0000-0003-4852-9395

(4) Instituto de Ensino e Pesquisa DASA, IEPD, São Paulo (SP), Brazil.

Correo eletrônico:
marcioluisduarte@gmail.com

ORCID: 0000-0002-7874-9332

ABSTRACT

Pachydermoperiostosis, also known as primary hypertrophic osteoarthropathy, is a rare hereditary disease characterized by soft tissue proliferation and periosteal new bone formation in long bones, classically presenting with digital clubbing, symmetric periostosis, and joint effusions. Imaging studies play a fundamental role in evaluating the extent of osteoarticular involvement. We report the case of a patient with pachydermoperiostosis with knee joint involvement, highlighting magnetic resonance imaging findings.
Key words: Pachydermoperiostosis; Hypertrophic osteoarthropathy; Magnetic resonance imaging; Synovitis; Periostosis

RESUMEN

La paquidermoperiostosis, también conocida como osteoartropatía hipertrófica primaria, es una enfermedad hereditaria rara caracterizada por proliferación de tejidos blandos y neoformación periostal de los huesos largos, manifestándose clásicamente por acropaquia digital, periostosis simétrica y derrames articulares. Los estudios de imagen desempeñan un papel fundamental en la evaluación de la extensión del compromiso osteoarticular. Presentamos el caso de un paciente con paquidermoperiostosis con afectación articular de las rodillas, destacando los hallazgos en la resonancia magnética.
Palabras clave: Paquidermoperiostosis; Osteoartropatía hipertrófica; Imagen por Resonancia Magnética; Sinovitis; Periostosis

RESUMO

A paquidermoperiostose, também conhecida como osteoartropatia hipertrófica primária, é uma doença hereditária rara caracterizada por proliferação de tecidos moles e neoformação periosteal dos ossos longos, manifestando-se classicamente por baqueteamento digital, periostose simétrica e derrames articulares. Os exames de imagem desempenham papel fundamental na avaliação da extensão do acometimento osteoarticular. Relatamos o caso de um paciente com paquidermoperiostose com acometimento articular dos joelhos, destacando os achados de ressonância magnética.
Palavras chave: Paquidermoperiostose; Osteoartropatia hipertrófica; Imageamento por Ressonância Magnética; Sinovite; Periostose

Date received: 01/04/2025
Acceptance date: 11/06/2026

DOI: 10.25184/anfamed2026v13n2a4

A 22-year-old man with a previous diagnosis of Touraine–Solente–Golé syndrome (primary hypertrophic osteoarthropathy), reportedly confirmed by genetic testing performed elsewhere, presented with chronic arthralgia and recurrent knee swelling. No clinical history suggestive of secondary hypertrophic osteoarthropathy was reported. Magnetic resonance imaging demonstrated marked bilateral joint effusion associated with chronic synovitis, metaphyseal widening of the distal femur, and diffuse thickening of the patellar tendon with deep infrapatellar bursitis (**Figure 1**). The imaging findings were consistent with articular involvement related to pachydermoperiostosis. Although periostosis is a hallmark feature of the disease, no periosteal reaction or cortical thickening was identified on the present MRI examination, which predominantly demonstrated articular manifestations including chronic synovitis and joint effusion.

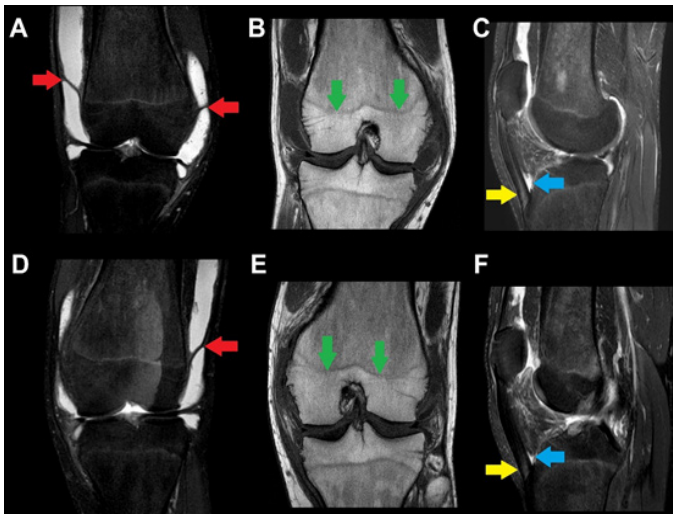

Figure 1. Magnetic resonance imaging of the knees in a patient with pachydermoperiostosis (Touraine–Solente–Golé syndrome). (**A–C**) Right knee: coronal proton density fat-suppressed (DP-SPIR), coronal T1-weighted, and sagittal DP-SPIR images. (**D–F**) Left knee: coronal DP-SPIR, coronal T1-weighted, and sagittal DP-SPIR images. Bilateral marked joint effusion is observed, associated with chronic synovitis (red arrows). Mild metaphyseal widening of the distal femur is noted (green arrows), without evidence of periosteal reaction or cortical thickening, patellar tendinopathy (yellow arrows), and deep infrapatellar bursitis (blue arrows).

Pachydermoperiostosis is a rare hereditary disorder characterized by the classic triad of digital clubbing, periostosis of long bones, and joint effusions[1]. The disease may occur in primary (genetic) or secondary forms[2]. Metaphyseal enlargement may reflect chronic periosteal and endosteal bone remodeling related to prolonged inflammatory and vascular changes seen in hypertrophic osteoarthropathy[2,3]. This finding may contribute to joint symptoms and may be an underrecognized imaging manifestation of pachydermoperiostosis, particularly in patients with long-standing disease. Recognition of metaphyseal widening associated with chronic synovitis and joint effusion may help radiologists suggest the diagnosis in the appropriate clinical setting and differentiate pachydermoperiostosis from secondary hypertrophic osteoarthropathy, acromegaly, and thyroid acropachy, which may present overlapping clinical features.

REFERENCES:

1. Abdullah NRA, Jason WLC, Nasruddin AB. Pachydermoperiostosis: a rare mimic of acromegaly. Endocrinol Diabetes Metab Case Rep. 2017;2017:17-0029. Doi: 10.1530/EDM-17-0029.
2. Yap FY, Skalski MR, Patel DB, Schein AJ, White EA, Tomasian A, et al. Hypertrophic osteoarthropathy: clinical and imaging features. Radiographics. 2017;37(1):157–195. doi: 10.1148/rg.2017160052.
3. Adams B, Amin T, Leone V, Wood M, Kraft JK. Primary hypertrophic osteoarthropathy: ultrasound and MRI findings. Pediatr Radiol. 2016;46(5):727–730. doi: 10.1007/s00247-016-3544-8.

Author contribution note:
Victor Sudário Takahashi: Conceptualization, Data curation, Formal analysis, Investigation, Methodology, Project administration, Validation, Visualization, Writing – original draft, Writing – review & editing.
Laura Gabriela Silva: Conceptualization, Data curation, Formal analysis, Investigation, Methodology, Project administration, Validation, Visualization, Writing – original draft, Writing – review & editing.
José Luiz Masson de Almeida Prado: Conceptualization, Data curation, Formal analysis, Investigation, Methodology, Project administration, Validation, Visualization, Writing – original draft, Writing – review & editing.
Márcio Luís Duarte: Data curation, Formal analysis, Funding acquisition, Investigation, Methodology, Validation, Visualization, Writing – original draft, Writing – review & editing.
Conflict of Interest: The authors declare that they have no conflict of interest.
Funding: There´s no funding.
This article does not contain any studies with animals performed by any of the authors.
Editor´s note: The editor responsible for the publication of this article is Liliana Servente.